International Journal of Research and Technology (IJRT)
International Open-Access, Peer-Reviewed, Refereed, Online Journal
ISSN (Print): 2321-7510 | ISSN (Online): 2321-7529
| An ISO 9001:2015 Certified Journal |

A Retrospective Study of Histopathological Spectrum of Ovarian Lesions Associated with Pregnancy over a period of 3 Years at a Tertiary Care Hospital

Dr.Saraff Gouripriya , Dr.Padmavathy Mudavath , Dr.Manisha Thavanam
gouripriya100394@gmail.com

Abstract

OBJECTIVE: The purpose of this Study was to subclassify histopathological spectrum of Ovarian Lesions Associated with pregnancy , over a period of 3 years at a tertiary care hospital.

METHODS: Out of 46 cases of pregnant women presented with ovarian lesions, 43 cases are asymptomatic at presentation, diagnosed on routine ultrasound scans , 2 cases presented with pain abdomen and 1 case presented with mass per abdomen. Among the 46 cases , 44 cases were benign and 2 cases were malignant on histopathological examination.
Mucinous Cystadenoma is the most common lesion associated with pregnancy, followed by Serous Cystadenoma and Dermoid cyst on histopathological examination. In 2 cases ovarian lesions were complicating pregnancy.
CONCLUSION: Ovarian lesions in pregnancy are usually diagnosed early due to routine antenatal checkups. Torsion of the ovarian lesion , rupture, malignancy are the complications and need to look after during pregnancy.
KeyWords: Torsion, Malignancy, Rupture

Introduction

Ovarian masses identified during pregnancy represent a heterogeneous group of functional cysts, benign neoplasms and less frequently borderline or malignant tumours. Increased use of obstetric ultrasonography facilitates recognition of incidental adnexal masses, but imaging alone does not always establish their histological nature. Published reports describe the diagnostic and management challenges posed by ovarian tumours during pregnancy [1–3,5].

Histopathological examination permits distinction among surface epithelial, germ cell, sex cord–stromal and pregnancy-related non-neoplastic lesions. Small institutional series have also illustrated the diversity of ovarian tumours associated with pregnancy [4]. The present study describes the clinicopathological characteristics of 46 cases at a tertiary-care hospital in Hyderabad.

Aim and objectives

To classify ovarian lesions associated with pregnancy according to histopathological diagnosis and describe patient age, gravidity, clinical presentation, gestational stage and preoperative clinicoradiological impressions.

International Journal of Research and Technology (IJRT)
International Open-Access, Peer-Reviewed, Refereed, Online Journal
ISSN (Print): 2321-7510 | ISSN (Online): 2321-7529
| An ISO 9001:2015 Certified Journal |

Materials and methods

Study design: Retrospective observational study conducted in the Department of Pathology at a tertiary-care hospital in Hyderabad, India. Study period: January 2021 to December 2023.

Study population: Forty-six ovarian lesions associated with pregnancy were included.

Data collection: Age, gravida, clinical presentation, stage of pregnancy, clinicoradiological impression and histological diagnosis were included.

Statistical analysis: Frequencies and percentages were calculated descriptively with a denominator of 46.

Results

Patient ages ranged from 20 to 34 years (mean 25.2 years). 40 of 46 records (87.0%) specified asymptomatic presentation; four (8.7%) were labelled “complicating pregnancy”, one “mass per abdomen” and one “PROM”.

Out of 46 cases , 18 cases presented in 3rd trimester, 10 cases presented in 2nd trimester, 7 cases presented in 1st trimester, 11 cases presented in term.

Out of 46 cases ,11 cases are mucinous cystadenomas, 9 cases are dermoid cysts, 9 cases are serous cystadenomas, 2 are with low malignant potential.

Remaining are cystadenofibromas, simple ovarian cysts, mucinous papillary cysts, luteal cysts.

Percentage of ovarian lesions associated with pregnancy:

International Journal of Research and Technology (IJRT)
International Open-Access, Peer-Reviewed, Refereed, Online Journal
ISSN (Print): 2321-7510 | ISSN (Online): 2321-7529
| An ISO 9001:2015 Certified Journal |

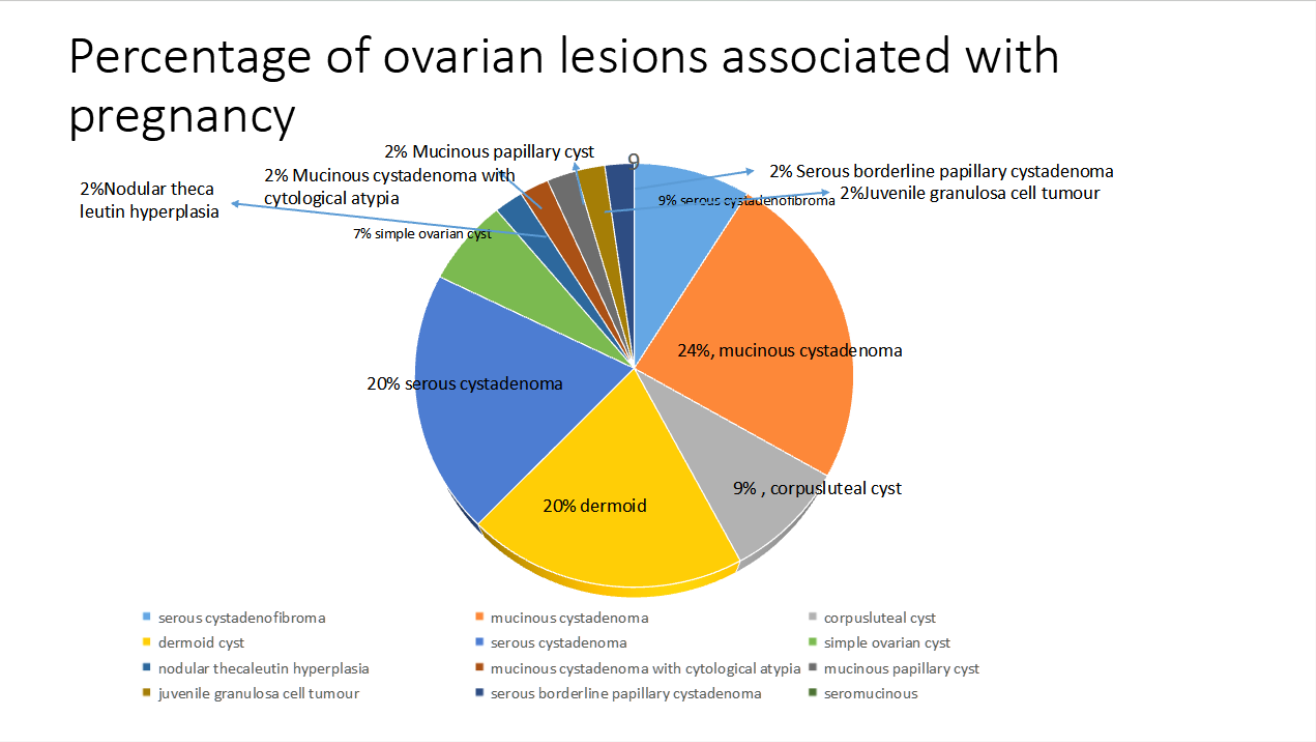

Discussion

This retrospective series shows that most pregnancy-associated ovarian lesions were recorded in asymptomatic patients, highlighting the role of routine antenatal imaging in their detection. The varied histopathological diagnoses demonstrate why a broad differential diagnosis is necessary.

Zanotti and colleagues reviewed treatment considerations for gynaecological cancers in pregnancy [1], while Dgani and colleagues described ovarian carcinoma during pregnancy in an Israeli case series [2]. Gezginc and colleagues also addressed ovarian cancer during pregnancy [3]. These reports provide clinical context for the uncommon neoplastic lesions encountered in the present series.

Surface epithelial ovarian tumour is the most common type of ovarian malignancy according to Gezginc K et al[3] study.

Dermoid cysts are the most common lesions associated with pregnancy according to O Tariel et al[5] study.

Mucinous cystadenoma is the commonest ovarian lesion associated with pregnancy in our study .In our study 2 cases are, granulosa cell tumour and serous borderline papillary cystadenoma low malignant potential focal micropapillary carcinoma.

Conclusion

Ovarian lesions associated with pregnancy include functional cysts, benign epithelial and germ-cell tumours, and uncommon borderline or potentially malignant neoplasms. Histopathological assessment remains central to definitive classification of surgically sampled lesions.

Ovarian lesions in pregnancy are usually diagnosed early due to frequent routine ultrasound examinations.

Torsion of the ovarian lesion, rupture, malignancy are the complications and need to look after during pregnancy.

Malignancy may be associated with pregnancy without any symptoms.

Clinicoradiological evaluation and histopathological examination of ovarian lesions are essential for accurate diagnosis and treatment.

References

1. Zanotti KS, Belinson JL, Kennedy AW. Treatment of gynecologic cancers in pregnancy. Semin Oncol. 2000;27:686–698.

2. Dgani R, Shoham Z, Atar E, Zosmer A, Lancet M. Ovarian carcinoma during pregnancy: a study of 23 cases in Israel between the years 1960 and 1984. Gynecol Oncol. 1989;33:326–331.

3. Gezginc K, Karatayli R, Yazici F, Acar A, Celik C, Capar M. Ovarian cancer during pregnancy. Int J Gynaecol Obstet. 2011;115(2):140–143. [Author list/spelling to verify.]

4. Saikia CJ, Bora K. Morphological spectrum of ovarian tumours associated with pregnancy: a series of ten cases. [Journal, year, volume, pages and DOI required.]

5. Tariel O, Huissoud C, Rudigoz RC, Dubernard G. Presumed benign ovarian tumors during pregnancy. J Gynecol Obstet Biol Reprod (Paris). 2013;42(8):842–855. [Verify title and bibliographic details.]